

# Gastroenteropancreatic neuroendocrine tumours

Irvin M Modlin, Kjell Oberg, Daniel C Chung, Robert T Jensen, Wouter W de Herder, Rajesh V Thakker, Martyn Caplin, Gianfranco Delle Fave, Greg A Kaltsas, Eric P Krenning, Steven F Moss, Ola Nilsson, Guido Rindi, Ramon Salazar, Philippe Ruszniewski, Anders Sundin

Gastroenteropancreatic (GEP) neuroendocrine tumours (NETs) are fairly rare neoplasms that present many clinical challenges. They secrete peptides and neuroamines that cause distinct clinical syndromes, including carcinoid syndrome. However, many are clinically silent until late presentation with mass effects. Investigation and management should be highly individualised for a patient, taking into consideration the likely natural history of the tumour and general health of the patient. Management strategies include surgery for cure (which is achieved rarely) or for cytoreduction, radiological intervention (by chemoembolisation and radiofrequency ablation), chemotherapy, and somatostatin analogues to control symptoms that result from release of peptides and neuroamines. New biological agents and somatostatin-tagged radionuclides are under investigation. The complexity, heterogeneity, and rarity of GEP NETs have contributed to a paucity of relevant randomised trials and little or no survival increase over the past 30 years. To improve outcome from GEP NETs, a better understanding of their biology is needed, with emphasis on molecular genetics and disease modeling. More-reliable serum markers, better tumour localisation and identification of small lesions, and histological grading systems and classifications with prognostic application are needed. Comparison between treatments is currently very difficult. Progress is unlikely to occur without development of centers of excellence, with dedicated combined clinical teams to coordinate multicentre studies, maintain clinical and tissue databases, and refine molecularly targeted therapeutics.

## Introduction


Although neuroendocrine tumours (NETs) have been regarded as fairly rare diseases, the US Surveillance Epidemiology and End Results (SEER) database suggests that their prevalence has increased substantially over the past three decades as awareness and diagnostic techniques have improved. However, analyses of UK and US databases also suggest no improvement in outcome over a similar period. On the basis of this database information, the US National Cancer Institute and US congressional committee for the National Institutes of Health appropriations have elevated NET disease and carcinoid tumours to number two in the priority for funding, after autism. Furthermore, the National Cancer Institute has mandated a summit conference to address the current status of the disease and to give recommendations for development of strategies for early diagnosis, identification of new targets, and effective management. Here, we review NETs from a biological and clinical perspective, and we give recommendations that take into account current scientific and clinical limitations that need to be addressed to facilitate improvement in management and outcome.

## Nomenclature

Tumours that are derived from the diffuse neuroendocrine system of the gastrointestinal tract and pancreas are fairly rare. They share some common clinical features, frequently have unpredictable and unusual biological behaviour, and frequently present late after delayed diagnosis. Targeted treatment is limited and management challenging because little is known about the cell biology and mechanistic regulation of these tumours.<sup>1</sup>

The understanding of gastroenteropancreatic (GEP) NETs has remained rudimentary since Siegfried Oberndorfer in 1907 first commented on tumours of the

small intestine and coined the term *karzinoide* (carcinoid, or cancer-like; figure 1).<sup>2</sup> Most GEP NETs arise from the gut or bronchopulmonary system, and these endocrine tumours are commonly called carcinoid tumours. Carcinoid is also a generic term for a characteristic syndrome that results from the intermittent release of bioactive amines into the systemic circulation that occurs in a few patients with GEP NET. Substantial confusion over the terminology for GEP NETs (such as their former classification as APUDomas) reflects past debate over the



**Figure 1:** Siegfried Oberndorfer first described and depicted carcinoid tumors in 1907

He initially considered them benign and “carcinoma-like”, before detailing their malignant behaviour in 1929.

*Lancet Oncol* 2008; 9: 61–72

Department of Gastroenterological Surgery, Yale University, New Haven, CT, USA (Prof I M Modlin MD); Endocrine Oncology Unit, Department of Internal Medicine, University Hospital Uppsala, Sweden (Prof K Oberg MD); Massachusetts General Hospital, Harvard University, Boston, MA, USA (D C Chung MD); Digestive Diseases Branch, National Institute of Diabetes and Digestive and Kidney Diseases, National Institutes of Health, Bethesda, MD, USA (R T Jensen MD); Department of Internal Medicine III, University Hospital Rotterdam, Erasmus Medical Centre, Rotterdam, Netherlands (W W de Herder MD); Academic Endocrine Unit, Nuffield Department of Clinical Medicine, University of Oxford, Oxford, UK (Prof R V Thakker MD); Neuroendocrine Tumour Unit, Centre for Gastroenterology, Royal Free Hospital, London, UK (M Caplin MD); Department of Digestive and Liver Disease, University of La Sapienza, Rome, Italy (Prof G Delle Fave MD); Department of Endocrinology, George Genimatas Hospital, Athens, Greece (G A Kaltsas MD); Department of Nuclear Medicine, Erasmus Medical Centre, Rotterdam, Netherlands (Prof E P Krenning MD); Division of Gastroenterology, Department of Medicine, Rhode Island Hospital, Brown University, Providence, RI, USA (S F Moss MD); Lundberg Laboratory for Cancer Research at the Department of Pathology, Sahlgrenska University Hospital, Gothenburg, Sweden (Prof O Nilsson MD); Department of Pathology and Laboratory Medicine, University of Parma, Parma, Italy (G Rindi MD); Department of Medical Oncology, Catalan Institute of Oncology, Barcelona, Spain (R Salazar MD);

Department of  
Gastroenterology, Beaujon  
Hospital, Clichy, France  
(Prof P Ruszniewski MD); Centre  
for Medical Imaging,  
Department of Radiology,  
Uppsala University, Uppsala,  
Sweden (A Sundin MD)

Correspondence to:  
Prof Irvin M Modlin, Department  
of Gastroenterological Surgery,  
Yale University, New Haven,  
CT 06520-8062, USA  
imodlin@optonline.net

origins of gut neuroendocrine cells.<sup>3</sup> Greater appreciation of the origins, heterogeneity, and molecular signatures of GEP NETs—and the various bioactive products they secrete—has given better insight into their biological and clinical heterogeneity.

### Epidemiology

GEP NETs are substantially rarer than adenocarcinomas; incidence is about 2.5 to 5 cases per 100 000.<sup>4</sup> About 0.46% of all malignant diseases are so-called carcinoid tumours of bronchopulmonary or gastrointestinal origin.<sup>4</sup> The incidence and prevalence of carcinoid tumours has increased substantially (figure 2), which may partly reflect increased diagnosis of benign and incidentally identified lesions due to increased availability of advanced endoscopic and radiological imaging. Clinical behaviour of GEP NETs varies strikingly, both in terms of symptoms and outcome. For example, overall 5-year survival for pancreatic NETs varies from 97% for benign insulinomas to 30% for those that are non-functioning and clinically silent.<sup>6</sup> These data necessitate reconsideration of the idea that GEP NETs are slow growing, fairly benign lesions.

Although some specialist centres report increased survival over time for GEP NETs, the SEER database (which reflects the standard of care for the average US individual) shows that the age-adjusted incidence of carcinoids of the small intestine and digestive system has increased by 460% and 720%, respectively, over 30 years. Furthermore, SEER shows increased prevalence over this period in white people (274%) and in black people (500%; 213% for men of all ethnicities and 286% for women of all ethnicities), an overall increase of 2.4-times in white people and four-times in black people. Although overall 5-year survival for carcinoid tumours of the small

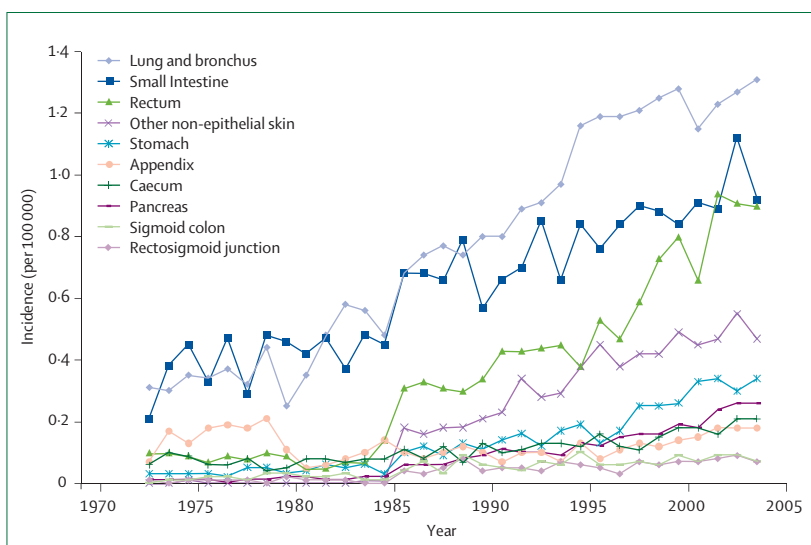
intestine is about 60%, this proportion has not changed substantially since 1973 (figure 3). This finding is disappointing and worthy of further investigation, and might be explained at least in part by a substantial lack of funding for this tumour type (figure 4).<sup>4</sup>

### Cell biology of gut neuroendocrine cells

Neuroendocrine cells occur throughout the length of the gut, and are the largest group of hormone-producing cells in the body (table 1).<sup>8</sup> They derive from local multipotent gastrointestinal stem cells, rather than by migration from the neural crest as first thought.<sup>3</sup> The mechanisms that underlie differentiation of cells of the diffuse endocrine-cell system are poorly understood. Transcription factors with a role in neuroendocrine-cell differentiation include protein atonal homolog 1 and neurogenin-3 (which also play a part in the differentiation of other granulocytic lineages), and neuroD. Loss-of-function mutations in neurogenin-3 in patients with congenital malabsorptive diarrhoea exemplify the importance of neurogenin-3 for enteroendocrine cell specification: mutant neurogenin-3 in these patients failed to promote neuroD transcription, resulting in specific loss of intestinal enteroendocrine cells.<sup>9</sup> At least 13 gut neuroendocrine cells exist, all of which produce various bioactive peptides or amines including serotonin, somatostatin, histamine, and gastrin (table 1). Secretory products are stored in large dense-core vesicles and small synaptic-like vesicles, and proteins of these vesicles (eg, chromogranin-A and synaptophysin) are markers of neuroendocrine cells.<sup>10</sup>

Secretion is regulated by G-protein-coupled receptors, ion-gated receptors, and receptors with tyrosine-kinase activity. Peptide hormones for regulated secretion are packaged into secretory granules (large dense-core secretory granules) that bud from the trans-Golgi network where prohormones and proneuropeptides are stored and processed before regulated secretion. Chromogranin-A regulates the biogenesis of dense-core secretory granules. Other granins (eg, chromogranin-B) regulate proteolytic processing of peptide precursors and promote aggregation-mediated sorting into mature secretory granules, enabling granules to mature into regulatable exocytotic carriers. Secretagogue-evoked stimulation induces actin reorganisation through sequential ordering of carrier proteins at the interface between granules and the plasma membrane. This calcium-dependent step is a prerequisite for regulated exocytosis, and it allows granule membrane trafficking and release of neuroendocrine contents.

Enterochromaffin cells are the major neuroendocrine cell type of the small intestine. They secrete various products in response to mechanical and chemical stimuli (table 1). Activating pathways for secretion of bioactive products include adenylyl cyclase,  $\beta$ -adrenoreceptors, and pituitary adenylyl cyclase-activating polypeptide, whereas somatostatin (via somatostatin receptor 2), acetylcholine (via muscarinic M4 receptors), and



**Figure 2: Increased incidence of carcinoid tumours, US population 1973–2005**  
Overall increase recorded for all primary sites during this period. Data from SEER database, US National Cancer Institute.<sup>5</sup>

gamma-aminobutyric acid (via gamma-aminobutyric acid A receptors) inhibit secretion.<sup>11</sup> Several receptor subtypes (1–7) for serotonin mediate its effects (eg, proliferation of epithelial cells and contraction of intestinal smooth muscle). Rapid inactivation of serotonin is crucial to limit its actions, which is achieved by uptake into neighbouring enterocytes and reuptake into enterochromaffin cells,<sup>11</sup> followed by intracellular conversion to 5-hydroxyindoleacetic acid by monoamine oxidase type A.

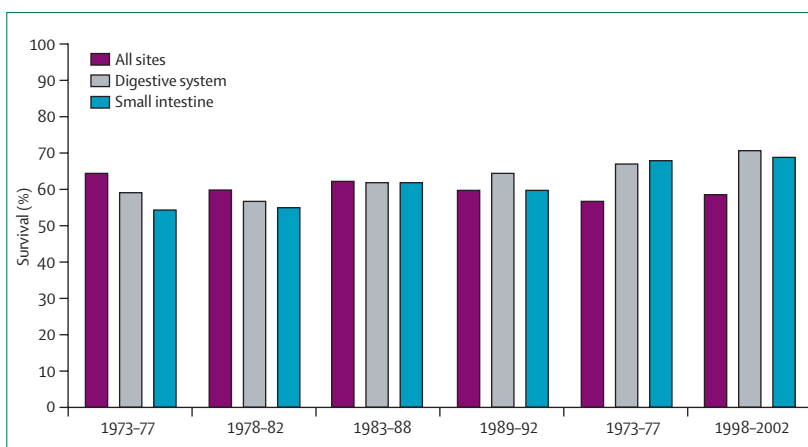
The apical part of the neuroendocrine cell frequently communicates with the gut through thin cytoplasmic extensions, which act as mechanosensors and chemosensors that project into the glandular lumen. The size, shape, and electron density of the secretory granules vary, representing important means for characterising different neuroendocrine cell types. Generally, different granules store individual peptide hormones; however, in some neuroendocrine cells, several different peptides or amines may colocalise in the same granule.<sup>12</sup>

Enterochromaffin-like cells of the gastric fundus are part of the gastric neuroendocrine cell system and interact with antral G cells, which secrete gastrin and activate enterochromaffin-like cells to produce histamine which in turn drives the parietal cells of the fundus to produce acid. Loss of parietal cells (eg, in atrophic gastritis) or acid suppression can lead to increased gastrin secretion, proliferation of enterochromaffin-like cells, and neoplasia (ie, gastric carcinoids).<sup>13</sup>

### Animal studies and cell lines

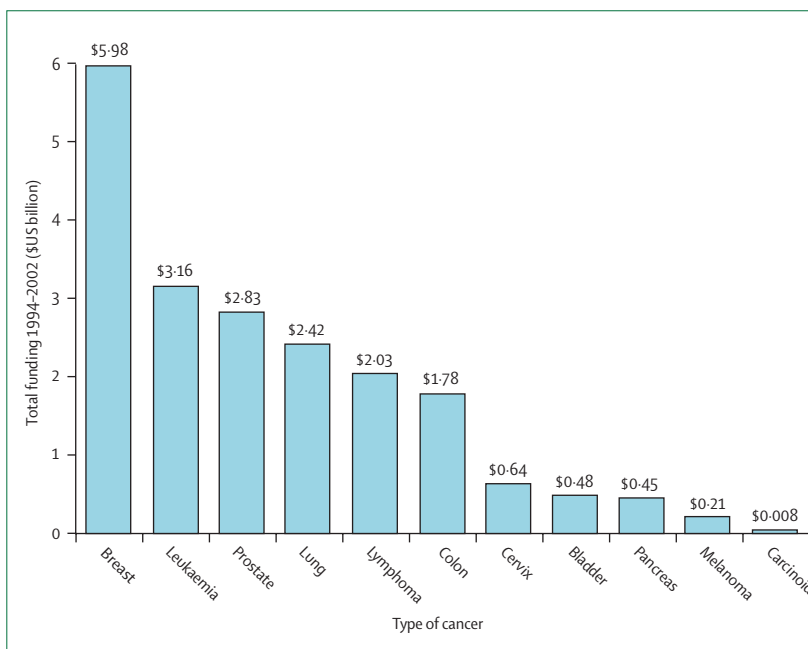
Animals that develop NETs and cell lines derived from human NETs might give insight into the pathogenesis of human GEP NET disease and enable rational development of molecularly targeted therapies, particularly if molecular pathogenesis in animals or cell lines mimics that of human GEP NETs. To date, preclinical findings have not successfully translated to the clinic, and most studies have had substantial limitations.

For example, expression of simian virus 40 (SV40) T antigen under the control of the insulin gene promoter results in pancreatic islet-cell tumours in mice,<sup>14</sup> but this model has limited clinical relevance because this antigen is not a driving force in human NETs. Mice with constitutively active cyclin-dependent kinase 4,<sup>15</sup> and double p18 and p27 knockout mice,<sup>16</sup> show NET phenotypes, suggesting cell-cycle dysregulation in human NET disease. Pancreatic neuroendocrine carcinomas have been induced in transgenic zebrafish that express N-myc.<sup>17</sup> Although there are several mouse models for pancreatic NETs, there are few for gastrointestinal carcinoids. Two small rodent species, *Mastomys natalensis* and the cotton rat, develop gastric carcinoids spontaneously—a propensity that can be accentuated substantially by acid suppression or elevation of plasma gastrin.<sup>18,19</sup> However, the use of these animals is limited by poor understanding of their genomes.



**Figure 3:** 5-year overall survival from carcinoids at all sites, carcinoids of the digestive system, and carcinoids of the small intestine, US population 1973–2002

Survival has not changed substantially during this period. Data from SEER database, US National Cancer Institute.<sup>5</sup>



**Figure 4:** US National Institutes of Health research funding for cancer 1994–2002

Carcinoid tumours (including NET) are the lowest funded cancer type for this period. Data from Computer Retrieval of Information on Scientific Projects database, US National Institutes of Health.<sup>7</sup>

A finding that is more relevant to the molecular pathogenesis of GEP NETs in humans is that mice with targeted deletion of the *menin* gene show key features of human multiple endocrine neoplasia 1 (MEN1) syndrome, which is caused by germline *menin* mutations.<sup>20–22</sup> Therefore, these mice are important physiological models of pancreatic NETs.

A scarcity of cultured human neuroendocrine cell lines has hindered the development of xenografts for therapeutic testing and modeling of clinical phenotypes. Two cell lines frequently used are BON1, derived from human pancreatic carcinoid,<sup>23</sup> and GOT1, derived from

Cell type	Localisation	Products	Factors that regulate secretion
D	Gastrointestinal tract	Somatostatin	Hormones, neural factors, and acid
Enterochromaffin	Gastrointestinal tract	Serotonin, substance P, guanylin, and melatonin	Luminal factors, hormones, and neural factors
Enterochromaffin-like	Stomach	Histamine	Hormones, gastrin, and neural factors
G	Stomach and duodenum	Gastrin	Amino acids, neural factors, and acid
Gr	Gastrointestinal tract	Ghrelin	Luminal factors and hormones
I	Duodenum	Cholecystokinin, gastrin, etc	Lipids and neural factors
K	Duodenum and jejunum	Gastric inhibitory polypeptide	Nutrients and hormones
L	Small intestine	Glucagon-like peptide, peptide YY, and neuropeptide Y	Glucose and hormones
Motilin	Duodenum	Motilin	Neural factors and luminal factors
N	Small intestine	Neurotensin	Lipids
S	Duodenum	Secretin	Acid
VIP	Gastrointestinal tract	Vasoactive intestinal peptide	Neural
X	Stomach	Amylin	Not defined

**Table 1: Types of gastrointestinal neuroendocrine cells and luminal, paracrine, neural, and hormonal factors that regulate secretion of their bioactive products**

liver metastasis of a human midgut carcinoid.<sup>11,24</sup> However, BON1 is not a pure neuroendocrine cell line and has probably acquired additional mutations *in vitro*, and GOT1 is maintained as a mouse xenograft. Of considerable interest is the recent characterisation of a pure human ileal carcinoid enterochromaffin cell line.<sup>11</sup> Establishment of a core cell-culture facility in a medical centre with high surgical volume may aid xenograft development.

### Molecular genetics

Studies have shown that the development of foregut, midgut, and hindgut NETs might involve different genes that are associated with distinct abnormalities, including point mutations, deletions, methylation, and chromosomal losses and gains.<sup>25–27</sup>

Foregut NETs have frequent deletions and mutations of the *menin* gene, encoding a protein of 610 aminoacids. *Menin* mutations cause most cases of MEN1 and a small proportion of sporadic foregut and non-gastrointestinal endocrine tumours. *Menin* is mainly a nuclear protein, but in dividing cells it interacts in the cytoplasm with several proteins that control transcription regulation, genome stability, and cell division.<sup>28</sup> Despite extensive information about *menin*, the genes involved in neuroendocrine tumorigenesis and the cellular roles of their proteins in proliferation or apoptotic pathways remain unknown. By contrast, hindgut NETs express transforming growth factor alpha and epidermal growth factor receptor.<sup>29</sup>

Given the emergence of functional genomics, expression profiling, and proteomics, both animal and

cellular models are necessary to investigate the molecular and genetic biology of NETs.

### Pathology

The 2000 WHO classification of endocrine tumours<sup>30</sup> clearly defined NET phenotypes by degree of differentiation, with specific related clinicopathological features according to tumour site of origin. Although this framework is helpful—especially for stomach, pancreatic, and duodenal tumours<sup>30,31</sup>—definitions of hyperplastic and dysplastic lesions and associated prognostic features are absent for the ileum and colon, and lesions of uncertain behaviour are poorly defined.

Furthermore, there is absence of uniformity and reproducibility of diagnosis between pathologists and institutions, mainly due to lack of adherence to the WHO classification (perhaps because it does not have a reliable and reproducible grading system).

Development of improved markers for individual stages of GEP NET tumorigenesis is needed to identify specific tissue or organ markers, and to integrate these markers with standard histological features. Such development might be achieved through emerging genomic and proteomic analyses.

### Clinical presentation

GEP NETs are fairly rare: diagnosis needs a high index of suspicion. These tumours synthesise, store, and secrete various peptides and neuroamines that might produce distinct syndromes.<sup>26,32</sup> Most GEP NETs are sporadic, but they can be multiple and part of a familial syndrome such as MEN1, von Hippel-Lindau syndrome, and neurofibromatosis type 1.

Clinical presentation depends on the site of the primary tumour and whether they are so-called functioning tumours—ie, whether the peptides secreted produce symptoms. Most GEP-NETs are non-functioning and present fairly late, with symptoms of mass effects or distant (usually hepatic) metastases, or both.<sup>26,32</sup> Although functioning tumours cause distinct clinical syndromes, individual symptoms are commonly mundane or not recognised as a complex. Delayed diagnosis is typical (5–7 years on average), increasing the probability of metastatic disease.

Gastric carcinoids are typically multiple, small, localised tumours associated with hypergastrinaemia, either secondary to chronic atrophic gastritis (type 1) or as part of Zollinger-Ellison syndrome (type 2). These tumours are benign or have low malignant behaviour; less than 2–5% metastasise. By contrast, large solitary gastric carcinoids (type 3) are not associated with hypergastrinaemia and commonly metastasise.<sup>26,32</sup> Most duodenal NETs are gastrin-secreting, causing Zollinger-Ellison syndrome and occurring in patients with MEN1.<sup>32</sup>

Carcinoid tumours derive from enterochromaffin cells of the diffuse neuroendocrine system and are mostly non-functioning.<sup>26</sup> The small intestine and appendix are

the commonest primary sites. Appendiceal carcinoids are usually small (ie, confined to the appendix) and identified incidentally during unrelated surgery or during acute appendicitis. Colon carcinoids are large tumours and have the poorest prognosis of all GEP NETs; patients commonly present with liver metastases. Rectal carcinoids are usually diagnosed incidentally during colonoscopy and are typically small, localised, non-functioning tumours that rarely metastasise (perhaps because of early detection).<sup>26,32</sup>

Most pancreatic NETs are large, up to 40% are non-functioning, and about 50% have hepatic metastases at diagnosis.<sup>32,33</sup> Functioning pancreatic NETs might secrete several peptide hormones and lead to diverse symptomatology. Insulinomas are typically small benign, functioning tumours, and patients present with hypoglycaemia.<sup>6,32</sup> Pancreatic gastrinomas are less common than duodenal gastrinomas, but are usually malignant; about 25% are associated with MEN1.<sup>6,32</sup> Glucagonomas, which cause diabetes and a characteristic rash (necrolytic migratory erythema), and VIPomas, which are associated with severe diarrhoea, are large tumours with metastases when diagnosed.<sup>32</sup> Other rare functioning tumours that secrete adrenocorticotropic hormone, growth hormone releasing hormone, parathyroid hormone-related protein, and somatostatin have been reported.<sup>32</sup> They may be difficult to diagnose because of intermittent peptide release, unusual symptoms, and fluctuating plasma hormone levels.<sup>6,32</sup>

Carcinoid tumours that originate in the distal jejunum and ileum commonly metastasise to the liver. Tumour size is an unreliable predictor of metastatic potential, and metastases can occur with primary tumours that are smaller than 1 cm in diameter. Typical carcinoid syndrome occurs in about 18% of patients with jejuno-ileal enterochromaffin tumours and is evident on identification of liver metastases. In the presence of liver metastases, serotonin, tachykinins, and other bioactive substances can reach the systemic circulation and cause carcinoid syndrome, characterised by cutaneous flushing, diarrhoea, and abdominal pain.<sup>26,32</sup> Moreover, liver involvement from metastatic disease might cause symptoms related to tumour bulk and capsular invasion.

A distinct feature of enterochromaffin tumours is their propensity to cause extensive mesenteric fibrosis and, occasionally, mesenteric ischaemia. Fibrosis might involve the endocardium of the right side of the heart and the tricuspid and pulmonary valves, with impairment of cardiac function. 10–20% of patients with carcinoid syndrome have heart disease at presentation. Treatment options for these patients include balloon valvuloplasty and bioprosthetic valve replacement, which can increase survival significantly.<sup>34</sup>

### Biochemical and tissue markers

Diagnosis of NETs is based on clinical presentation, hormone assays, and pathology. Some biochemical markers that are identifiable in body fluids suggest

Serum markers		Specificity
<b>General diagnostic use</b>		
Various	Chromogranin-A, chromogranin-B	High
	Pancreatic polypeptide, neuron-specific enolase	Intermediate
	Choriogonadotropin $\alpha$ chain, choriogonadotropin $\beta$ chain	Low
<b>Specific diagnostic use</b>		
Thymus	Adrenocorticotropic hormone	Intermediate
Bronchus	Adrenocorticotropic hormone, antidiuretic hormone, serotonin (urinary 5-hydroxyindoleacetic acid)	Intermediate
	Histamine (U-methylimidazole acetic acid), gastrin-releasing peptide, growth hormone releasing hormone, vasoactive intestinal peptide, parathyroid hormone related protein	Low
Stomach	Histamine, gastrin	High
	Ghrelin	Low
Pancreas	Gastrin, insulin, pro-insulin, glucagon, somatostatin	High
	Proinsulin C-peptide, neurotensin, vasoactive intestinal peptide, parathyroid hormone related protein, calcitonin	Intermediate
Duodenum	Somatostatin, gastrin	High
Ileum	Serotonin (urinary 5-hydroxyindoleacetic acid),	High
	Neurokinin A, neuropeptide K, substance P	Intermediate
Colorectum	Peptide YY, somatostatin	Intermediate

**Table 2: Serum markers with diagnostic and prognostic use in GEP-NET**

specific tumours, whereas others are common to several GEP NET types (table 2).<sup>32,33</sup> Correlation of serum markers with symptomatology and lesion location is important to facilitate accurate diagnosis.

For carcinoid tumours of the gastrointestinal tract, the breakdown product of serotonin, 5-hydroxyindoleacetic acid, can be measured in a urine sample obtained over 24h; food and drug restrictions are necessary for standardisation. For pancreatic NETs, serum markers relate to specific clinical syndromes. For insulinomas, these markers include insulin and proinsulin C-peptide (table 2); fasting for 24–72 h can increase the sensitivity of these markers, but might provoke severe hypoglycaemia. Plasma gastrin levels are elevated in most gastrinomas, and the sensitivity of this measurement can be increased by secretin or infusion of calcium.<sup>35</sup>

Markers common to many types of GEP NETs include chromogranin-A—a soluble secretory glycoprotein normally contained in neuroendocrine cell vesicles (table 2). Plasma assays for intact chromogranin-A and cleavage products released by specific NETs are available. Levels of circulating chromogranin-A are increased in 60–80% of GEP NETs and are especially useful in the diagnosis of non-functioning tumours. However, increased levels of this marker also occur with renal failure and with hyperplasia of enterochromaffin-like cells caused by proton-pump inhibitors and chronic atrophic gastritis.<sup>32,33,36</sup>

Other serum markers that are frequently elevated in NETs include neuron-specific enolase and chorionic gonadotropin (the latter can suggest a more-malignant phenotype).<sup>32,33</sup> Pancreatic polypeptide, which is produced by normal pancreatic islets, by pancreatic NETs, and

	Role	Use	Sensitivity
Chromogranin-A, synaptophysin, neuron-specific enolase	Histopathological identification and classification	Identification of neuroendocrine neoplasia	High
KI-67 antigen	Proliferation index	Assessment of rate of cell proliferation	High
Protein families of: transforming growth factor $\alpha$ ; transforming growth factor $\beta$ ; vascular endothelial growth factor; and epidermal growth factor	Growth factors and regulators of proliferation	Assessment of regulatory mechanisms and potential targets of novel therapeutic agents	Intermediate
Receptors for: somatostatin (subtypes 1–5); cholecystokinin; vasoactive intestinal peptide; pituitary adenylate cyclase-activating polypeptide; tachykinin; serotonin; and dopamine	Hormone receptors	Assessment of receptor-specific treatment; for somatostatin, assessment of therapeutic effectiveness with somatostatin analogues (either cold or radioisotopically labelled)	Somatostatin receptors: high; serotonin receptors: intermediate; other receptors: low to unproven
AF-10, insulin-like growth factor binding protein 3, P21 (cyclin-dependent kinase inhibitor 1), P27, CD99 antigen, transcription factor jun-D	Oncoproteins or cell-cycle control proteins	Indicators of proliferation and potential for aggressive behaviour and metastasis	Low to unproven
Neural cell adhesion molecule 1, CDX2, transcription termination factor 1, synaptic vesicle glycoprotein	Regulators of cell function	Indicators of neuroendocrine differentiation and potential for aggressive behaviour	Low to unproven

**Table 3:** Tissue markers with diagnostic and prognostic use in GEP-NET

sometimes by gastrointestinal carcinoids, is raised in 40–80% of pancreatic tumours. Adrenomedullin, a polypeptide hormone involved in angiogenesis, has some prognostic use in neuroendocrine carcinomas.<sup>37,38</sup>

Useful immunohistochemical tumour-tissue markers include many serum peptides and others that can be identified only in the tumour (eg, synaptophysin and the related markers synaptic vesicle glycoprotein 2 and synaptobrevin 1, neural cell adhesion molecule 1, CDX2, transcription termination factor 1, and peptide-hormone receptors; table 3).<sup>37</sup> The proliferation marker KI-67 antigen helps determine tumour grade and prognosis. Synaptophysin, an integral membrane glycoprotein found in presynaptic neuronal vesicles and in the small clear vesicles of normal and neoplastic neuroendocrine cells, is expressed independently of other neuroendocrine markers in poorly differentiated NETs. Neural cell adhesion molecule 1, a cell-surface glycoprotein neural-cell adhesion molecule, is expressed by neuronal cells and NETs. The transcription factor CDX2, which regulates intestine development, is a reliable marker of gut enterochromaffin-cell NETs, and transcription termination factor 1, which activates surfactant production in the lung, is a marker for aggressive pulmonary NETs.<sup>39</sup>

Although NET markers exist, sensitive and specific markers that predict tumour growth and behaviour are absent. Ideally, such markers should be able to detect lesions of fewer than 1 million cells and circulating tumour cells. Studies that use proteomics and tissue arrays are needed to develop new sensitive biochemical and tissue markers.

### Topographic diagnosis

Assessment of the location and extent of GEP NETs is crucial for management. Commonly used imaging modalities include: conventional radiology (ie, transabdominal ultrasonography, CT, and MRI); selective angiography, with or without hormonal sampling; nuclear imaging (eg, somatostatin-receptor scintigraphy [SRS] with single photon emission CT [SPECT], and bone scanning);

endoscopic ultrasonography; and various intraoperative methods (figure 5). No technique is 100% sensitive, and multiple imaging modalities might be needed to detect small, biochemically diagnosed tumours. Several new modalities to increase sensitivity for identification of micrometastasis while retaining specificity are under assessment.

At present, the primary tumour is not localised in 20–50% of GEP NETs; gastrinomas and carcinoids of the small intestine are particularly elusive. Conventional imaging for pancreatic NETs localises only 10–60% of primary tumours. Generally, detection frequency for MRI or CT is about 22–45%, which is higher than ultrasonography (13–27% detection frequency).<sup>40</sup> Angiography locates about 40–75% of lesions, and SRS has a sensitivity of 57–77% for non-insulinomas and 25% for insulinomas. Endoscopic ultrasonography can detect 45–60% of duodenal lesions and 90–100% of pancreatic lesions;<sup>41</sup> assessment of hormonal gradients during angiography is 80–100% sensitive.<sup>42,43</sup> For identification of hepatic metastases, SRS is the most-sensitive modality (81–96%, compared with 50–90% for angiography, 55–70% for MRI, and 14–63% for ultrasonography).<sup>42,43</sup> All modalities can frequently miss small liver metastases (ie, tumours <0.5 cm in diameter), underestimating true disease extent. The sensitivity of scintigraphy by use of meta-iodobenzylguanidine (MIBG) is inferior to SRS.<sup>42</sup> An important limitation of all available imaging modalities is that they give little prognostic information. Overall, a higher tumour burden and negative SRS scan are associated with a worse prognosis.

The recent introduction of SPECT-CT and PET-CT hybrid systems gives fusion images to correlate anatomical location with function. PET with 18-fluorodeoxyglucose ([<sup>18</sup>F]FDG) is not useful for NETs, except for highly aggressive tumours.<sup>44</sup> NETs take up decarboxylate amine precursors, and thus carbon-11 [<sup>11</sup>C]-labelled and <sup>18</sup>F-labelled amine precursors such as serotonin and levodopa can be

used.<sup>45,46</sup> In carcinoid tumours, PET with [<sup>18</sup>F]levodopa performs better than does SRS, with the reverse situation for non-carcinoid NETs.<sup>46</sup> PET with [<sup>11</sup>C]serotonin is more effective than CT and SRS, gives complementary diagnostic information about small tumours, detects possible recurrences, and visualises occult tumours.<sup>47</sup> Gallium-68 [<sup>68</sup>Ga] is a generator-produced positron emitter that does not need an in-house cyclotron. Current data suggest that PET with [<sup>68</sup>Ga-DOTA]-D-Phe(1)-Tyr(3)-octreotide effectively identifies metastatic NETs;<sup>48</sup> however, [<sup>68</sup>Ga] generators are not widely available. Moreover, PET can be done 1 h after injection of a [<sup>68</sup>Ga]-labelled somatostatin analogue compared with 24–48 h for SRS, and spatial resolution of PET is better than with SRS-SPECT.

Technical developments in ultrasonography with intravenous contrast media have facilitated the characterisation and detection of liver metastases and primary pancreatic NETs.<sup>49</sup> Dynamic examination allows assessment of the temporal and spatial contrast-enhancement pattern in the tumour in arterial, venous, and late phases. Liver metastases as small as 3 mm in diameter might be detected and equivocal findings characterised. Dynamic MRI with new contrast agents such as ultrasmall superparamagnetic iron oxide can analyse early perfusion and late reticuloendothelial uptake, and can assess lymph nodes, leading to improved detection of metastasis.<sup>50</sup> Molecular MRI with antibodies or gadolinium-labelled peptides can detect receptors on tumours and identify specific tumoral antigens such as ERBB2, which might give prognostic information.<sup>51</sup> Furthermore, molecular MRI might enable assessment of the efficacy of antitumour agents.<sup>52</sup> However, neither contrast-enhanced ultrasonography nor dynamic MRI has been assessed in the setting of NETs. Video capsules and small-bowel endoscopy can identify primary NETs of the small intestine and are useful in patients with metastatic disease from unknown primaries after CT and enteroclysis studies.<sup>53</sup> An endoscopic strategy that uses double-balloon enteroscopy, although more invasive, has potential.<sup>54</sup>

## Treatment

Treatment should be highly individualised based on the diverse range of tumour burden and symptoms. The best therapeutic choice for individual patients will depend on whether the main aim of treatment is to slow tumour growth or ameliorate symptoms by inhibition of the secretion of bioactive agents. Critical assessment of every treatment option is difficult because of the limited number of patients in a centre and the inability to classify accurately a heterogeneous group of lesions.

Furthermore, there are no clearly defined measures to predict which tumours will respond to a particular modality or to assess rigorously therapeutic efficacy. Management algorithms have been proposed for several GEP NETs,<sup>55</sup> but their assessment will take at least 5 years.

Establishment of regional centres for disease management, multicentre studies that assess prospective translational endpoints, and blood and tissue banking are needed to address therapeutic strategies.

## Surgery

Surgery is essential in many phases of GEP NET management, and in those with limited disease remains the primary method of cure.<sup>6,26,56</sup> For patients with advanced disease, cytoreductive surgery is recommended for palliation and increased survival; however data for these recommendations are not robust and need multicentre prospective assessment.<sup>56,57</sup> For those with unresectable disease, surgery can obviate bowel obstruction from small-bowel carcinoid fibrosis,<sup>58</sup> and extensive surgery can be done with acceptable morbidity and mortality (range 0–5%).<sup>59</sup>

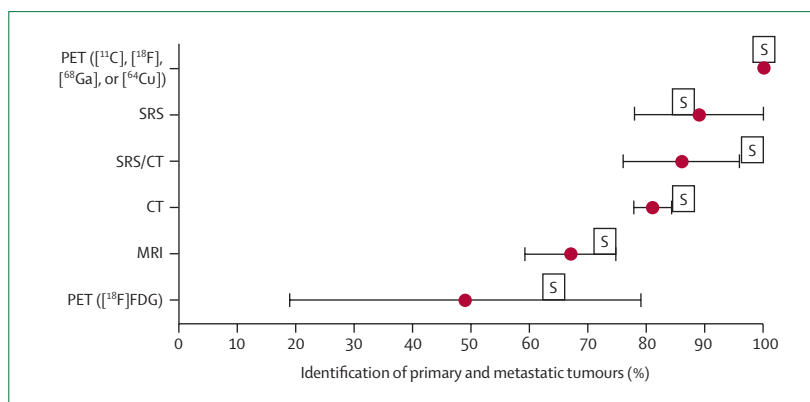
The main limitation of surgery is that more than 80% of patients have liver or lymph-node metastases, or both; contemporary methods before or during surgery that give information about micrometastases or localised metastases smaller than 0.5 cm in diameter are inadequate. Intraoperative radionuclide detection after SRS is not useful, particularly in the upper abdomen, because of the high background radiation count and lack of collimators with adequate discriminatory capability. These issues frequently render decisions about the extent of surgery arbitrary.

## Insulinomas

90–100% of patients have enucleation and occasionally resection, and 85–95% are cured. More than 99% of insulinomas are intrapancreatic and therefore a thorough search of the pancreas with intraoperative ultrasonography is recommended.<sup>56</sup>

## Gastrinomas

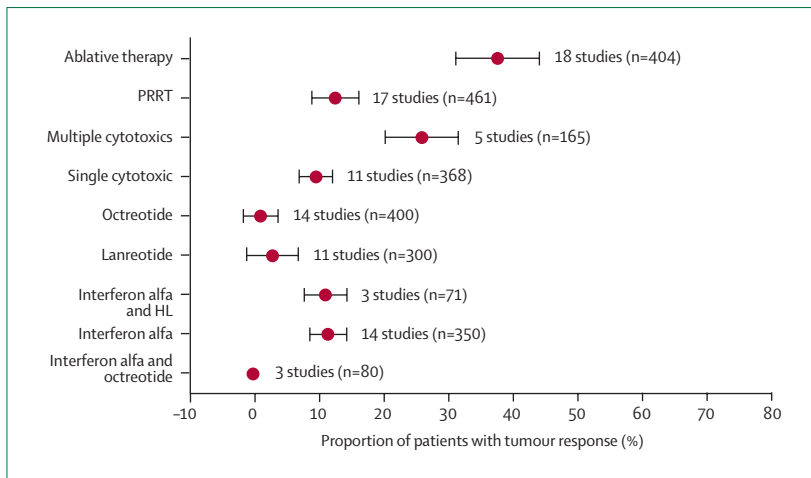
45–65% of patients are disease-free after surgery, and 35% remain so at 5 years. 60–80% of tumours are



**Figure 5: Methods for identification of primary and metastatic GEP-NET**

Data are pooled from 41 studies, and are median (range). Data for specificity and sensitivity are not comparable across studies. S=calculated sensitivity. <sup>11</sup>C=carbon-11. <sup>18</sup>F=fluorine-18. <sup>68</sup>Ga=gallium-68. <sup>64</sup>Cu=copper-64.

SRS=somatostatin receptor scintigraphy. FDG=fluorodeoxyglucose. Adapted with permission from reference 40.



**Figure 6: Treatment response for gastrointestinal NET**

\*Radiofrequency, cryoablation, and chemoembolisation of liver metastases. PRRT=peptide receptor radionuclide therapy. HL=human leucocyte interferon. Adapted with permission from reference 40.

duodenal and therefore routine duodenotomy and duodenal transillumination are important.<sup>60</sup> Duodenal lesions are characteristically small (ie, <0.1 cm in diameter) and not usually detected on imaging. Standard surgery is enucleation or local resection.<sup>61</sup>

**Other pancreatic NETs and carcinoids of the small bowel and colon**  
Most patients present with extensive metastatic disease, limiting the likelihood of curative surgery; however, resection to avoid obstruction or bleeding may benefit patients.<sup>6</sup>

#### Primary gastrointestinal carcinoids

Many of these tumours of the stomach, duodenum, or rectum are smaller than 1 cm in diameter and can be cured endoscopically if they are uninvasive. Otherwise, en bloc resection is needed.<sup>26</sup>

#### Liver metastases

Hepatic spread occurs in 50–75% of small-bowel carcinoids, 5–70% of foregut carcinoids, and 14% of hindgut carcinoids.<sup>46</sup> 30–85% of pancreatic NETs have hepatic metastasis<sup>6</sup> and are potentially completely resectable in only 7–15% of patients.<sup>39</sup> The presence of liver metastases worsens surgical outcome. Enucleation, or extensive hepatic resections with or without ablations are usually needed, but less than 15% of patients are cured. In rare individuals, such as young patients with metastatic NETs limited to the liver, liver transplantation might be necessary for cure.<sup>62</sup>

#### Improved outcomes

Two main goals need to be accomplished to improve surgical outcomes. First, to individualise surgical approach, methods are needed to determine precisely the tumour extent (eg, presence of micrometastases,

regional lymph-node involvement, or distant metastases) and the tumoral prognostic factors before and during surgery. Intraoperative hand-held radiation detectors to image micrometastases by use of labelled monoclonal antibodies or other tumour-specific molecules is available for other cancer types.<sup>63</sup> Detection of photofors or sensitizers that specifically target neoplastic lesions might be possible intraoperatively, but these approaches need development of probes that are specific for NET antigens. Second, there is a need to develop methods to reduce the burden of liver metastases to enable all patients to become candidates for cytoreductive surgery.

#### Interventional radiology

Most liver metastases from NETs are hypervascular, and embolisation of the hepatic artery by particles or cytotoxic agents effectively generates necrosis. Combination of cytotoxic agents with 10 mL iodised oil can be injected into the branches of the hepatic artery distal to the gastroduodenal artery. Embolisation with gelatine sponge particles or microspheres is used until evidence of a marked decrease in blood flow. However, randomised controlled trials that compare the benefits and risks of mechanical embolisation with that by cytotoxic agents are lacking.

Contraindications for embolisation are complete portal-vein thrombosis, liver insufficiency, and previous Whipple procedure. Concomitant antibiotics and somatostatin analogues are used to avert a carcinoid crisis and diminish the possibility of hepatic abscess. Although chemoembolisation with doxorubicin, streptozocin, mitomycin, and fluorouracil has been used for 15 years, there are no randomised studies of this technique.<sup>64</sup> Long-lasting complete or partial clinical responses (ie, improved symptoms or performance status) have been noted in about 80% of patients given chemoembolisation. Median time to progression is about 15 months; 5-year survival is about 50%. Adverse events include a postembolisation syndrome of pain, fever, and elevated liver enzymes, which occurs in 90% of patients. Severe events, including acute liver or renal failure, carcinoid crisis, cholecystitis, or bleeding peptic ulcers, occur in about 10% of patients;<sup>65,66</sup> treatment-related deaths are very rare.

Whether chemotherapy given with embolisation has an advantage over embolisation alone is unclear. Particles or spheres that contain the cytotoxic drug might facilitate an all-in-one procedure. Moreover, radionuclide-labelled microspheres or coupling of embolisation with radioactive somatostatin analogues might improve outcome. In patients with large tumours (ie, more than >3 cm in diameter), radiofrequency ablation in conjunction with chemoembolisation might be more effective than chemoembolisation alone. However, the role of radiofrequency ablation in the



	Target and mechanism	Type of trial	Partial response (proportion of patients)*	Reference
Bevacizumab	Monoclonal antibody against vascular endothelial growth factor	Randomised phase II trial	18%	72
Sunitinib	Tyrosine kinase inhibitor of vascular endothelial growth factor receptors 1–3, platelet-derived growth factor receptor, KIT, RET ligand 1, and FLT 3,	Phase II trial of patients with carcinoid tumours or islet- cell tumours	2% (carcinoid); 15% (islet cell)	73
Sorafenib	Tyrosine kinase inhibitor of vascular endothelial growth factor receptors 2–3, platelet-derived growth factor receptor, FLT3, BRAF, KIT, and fibroblast growth factor receptor 1	Phase II trial	Ongoing trial	NA
Vatalanib	Tyrosine kinase inhibitor of vascular endothelial growth factor receptors 1–3, platelet-derived growth factor receptor, and KIT	Phase II trial	Ongoing trial	NA
Temsirolimus	Protein kinase inhibitor of mTOR	Phase II trial of patients with carcinoid tumours or islet-cell tumours	5% (carcinoid); 7% (islet cell)	74
Everolimus	Protein kinase inhibitor of mTOR	Phase II trial of patients with carcinoid tumours or islet-cell tumours	12% (carcinoid); 15% (islet cell)	75

\*Defined according to WHO or RECIST (Response Evaluation Criteria in Solid Tumors)<sup>76</sup> criteria. NA=not available.

**Table 4: New treatments for GEP-NET**

overall management of NET disease remains poorly defined.<sup>67</sup> The use of large so-called umbrella radiofrequency ablation tips for large tumours up to 5 cm in diameter, and the combination of radiofrequency ablation with intratumoral injection of cytotoxic agents, antiangiogenic agents, or alcohol, might further aid tumour destruction.

### Medical treatment

The aims of medical treatment can be defined broadly as amelioration of symptoms and suppression of tumour growth and spread. Symptom relief can be achieved with somatostatin analogues. However, various chemotherapeutic agents alone or in combination have been fairly ineffective for suppression of tumour growth and spread (figure 6).

#### Somatostatin analogues and interferon

Somatostatin analogues remain the mainstay of symptomatic treatment for GEP NETs. To date, the most effective formulations include lanreotide autogel (60 mg, 90 mg, or 120 mg) and long-acting octreotide (10 mg, 20 mg, or 30 mg), which are widely accepted as effective in controlling tumour-related symptoms in about 75% of patients and in reducing serum concentration of tumour markers. These drugs are well tolerated and safe, with mild adverse effects and high tolerability after sustained use. Their effects on tumour growth are limited: less than 5% of patients have objective radiological tumour regression, although about 50% of patients have stabilisation of tumour size.<sup>68,69</sup>

Interferon has a high response frequency in terms of symptomatic and biological response (about 80% of patients), but has substantial concomitant adverse effects. There is no evidence that addition of interferon to somatostatin analogues increases tumour response.

However, this combination leads to a significantly lower risk of progressive disease compared with somatostatin analogues alone, and has a higher median survival (51 vs 35 months).<sup>70</sup>

#### Chemotherapy

Cytotoxics are regarded the first-line treatment for poorly differentiated or rapidly progressive GEP NETs. Etoposide plus cisplatin has some effectiveness in poorly differentiated tumours, whereas streptozocin with fluorouracil or doxorubicin benefits patients with pancreatic NETs by reducing radiological tumour load by more than 30% in about a third of patients.<sup>71</sup>

The crucial issue with rigorous assessment of medical treatment is that most studies are retrospective, assess heterogeneous tumours, commonly lack standardised entry criteria, reflect single-centre experience, and are underpowered.

#### Panel: Requirements for an improvement in NET outcome

- Refinement of universal classification and grading system
- Elucidation of cell biology
- Development of cell lines and animal models
- Acquisition of genetic information
- Identification of serum markers for early diagnosis
- Definition of tissue markers to identify tumour origin
- Development of molecular pathological profiling to define prognosis
- Precise identification of topographic information (before and during surgery)
- Identification of molecular therapeutic targets
- Development of improved (adjuvant) treatment for residual disease
- Establishment of centres of excellence and multidisciplinary speciality NET clinical teams
- Construction of central clinical and tissue database resources
- Government focus on clinical and research funding for an orphan disease

### New drugs and targets

Traditional DNA-damaging cytotoxic drugs are of limited efficacy in GEP NETs. Several proangiogenic molecules are overexpressed in NETs—eg, vascular endothelial growth factor and its receptors, and related signalling-pathway components such as epithelial growth factor receptor, insulin-like growth factor 1 receptor, phosphoinositide-3-kinase, RAC-alpha serine/threonine-protein kinase (AKT), and mammalian target of rapamycin (mTOR). New drugs that target some of these molecules are under assessment in early clinical trials (table 4).<sup>72-75</sup> Angiogenesis and mTOR inhibitors might have potential, although less than 20% of patients have a radiological response.

Although strategies that use these biological agents might advance the management of GEP NETs, they were first developed for other tumour types. The development of more effective drugs for GEP NETs will need improved understanding of GEP NET biology and perhaps the discovery of a molecular target specific to all or some subtypes of GEP NETs. Use of somatostatin receptors to target so-called passenger drugs (ie, active cytotoxic drugs that are physically linked to agents that bind to somatostatin receptors) might hold potential.

### Peptide-receptor radionuclide therapy

This new treatment has proven to be safe and effective<sup>77</sup> and might become an important treatment strategy for lesions that express adequate densities of somatostatin receptors. GEP NETs overexpress these receptors, mainly subtype 2, which become internalised after ligand binding. Therefore, they are targets for cytotoxic drugs coupled to somatostatin (eg, radiolabelled somatostatin analogues). Diagnostic SRS with indium-111-labelled DTPA<sup>o</sup>-octreotide ([<sup>111</sup>In]octreotide) can identify tumours that express somatostatin receptors and that are thus suitable for peptide-receptor radionuclide therapy. Initially, this treatment used high-dose [<sup>111</sup>In]octreotide. Subsequently, somatostatin peptides with higher receptor affinity were developed and conjugated with the chelator 1,4,7,10-tetraazacyclododecane-1,4,7,10-tetraacetic acid (DOTA), allowing stable labelling with the pure, high-energy  $\beta$ -emitter yttrium-90 or the medium-energy  $\beta$ -emitter lutetium-177 ([<sup>177</sup>Lu]). Conjugation of octreotide with a chelator can change the affinity profile for particular subtypes of somatostatin receptor. [<sup>177</sup>Lu]DOTATATE ([<sup>177</sup>Lu]DOTA-Tyr[3]-octreotate), a selective analogue of somatostatin receptor 2, has a particularly favourable affinity profile. Its maximum tolerated dose is limited by toxic effects on the kidney and bone marrow, and results seem encouraging compared with historical therapeutic data.<sup>77</sup>

Randomised studies of peptide-receptor radionuclide therapy are lacking, making comparison of published data difficult. Whether the addition of radiosensitisers such as capecitabine (an oral derivative of fluorouracil) or a combination of radionuclides with different physical

### Search strategy and selection criteria

Data for this review were identified by searches of MEDLINE and PubMed, and references from relevant articles using the search terms “Neuroendocrine” or “carcinoid” and “tumor”. Abstracts and reports from meetings were included only when they related directly to previously published work. Data published from Jan 1, 1970, to June 30, 2007, were included.

characteristics will increase efficacy remains to be determined. If peptide-receptor radionuclide therapy is licensed and becomes widely available, it will likely be used in combination with other treatments in SRS-positive GEP NET disease.

### Conclusion

GEP NETs are unusual and fairly rare neoplasms. Although recognised for at least a century, they remain orphan tumours, about which little is known. Disappointingly, survival of patients with NETs has not changed appreciably over the past three decades in either the USA<sup>4</sup> or UK.<sup>78</sup> Improved cell lines and models are needed to define their derivation, biology, behaviour, and growth potential.

Many different types of physicians manage GEP NETs, including endocrinologists, gastroenterologists, oncologists, interventional radiologists, and surgeons. Moreover, strategies vary depending on tumour type, spread, general health of the patient, and predominant symptoms. More reliable serum markers and better tumour localisation and identification would be of great benefit. There is a relative paucity of genetic information and poor application of the histological grading systems and classifications that have been devised. Comparison between treatments is difficult because of heterogeneous patients and few randomised trials. The development of centres of excellence and NET clinical teams to coordinate multicentre studies, extend clinical and tissue databases, and ultimately develop molecularly targeted therapeutics are needed to advance treatment and survival for patients with GEP NETs (panel).

### Conflicts of interest

All authors have received honoraria and travel support to attend national and international meetings for neuroendocrine tumours from Novartis, Ipsen, Schering Plough and/or Pfizer. The group meetings that enabled the material for this Review to be assembled were supported by an unrestricted educational grant from Ipsen, which did not participate in data compilation or in the writing or viewing the submitted Review. The corresponding author has had full access to all the data, warrants that all information has been reviewed and accepted by all participants, and is responsible for the decision to submit this Review for publication.

### References

- 1 Barakat MT, Meeran K, Bloom SR. Neuroendocrine tumours. *Endocr Relat Cancer* 2004; **11**: 1–18.
- 2 Oberndorfer S. Karzinoide Tumoren des Dünndarms. *Frankf Z Pathol* 1907; **1**: 426–32.

- 3 Pearse AG. The cytochemistry and ultrastructure of polypeptide hormone-producing cells of the APUD series and the embryologic, physiologic and pathologic implications of the concept. *J Histochem Cytochem* 1969; **17**: 303–13.
- 4 Modlin IM, Lye KD, Kidd M. A 5-decade analysis of 13 715 carcinoid tumors. *Cancer* 2003; **97**: 934–59.
- 5 US National Cancer Institute. SEER Database. <http://seer.cancer.gov/> (accessed Nov 15, 2007).
- 6 Oberg K, Eriksson B. Endocrine tumours of the pancreas. *Best Pract Res Clin Gastroenterol* 2005; **19**: 753–81.
- 7 US National Cancer Institute. CRISP Database. <http://crisp.cit.nih.gov/> (accessed Nov 15, 2007).
- 8 Rehfeld JF. The new biology of gastrointestinal hormones. *Physiol Rev* 1998; **78**: 1087–108.
- 9 Wang J, Cortina G, Wu SV, et al. Mutant neurogenin-3 in congenital malabsorptive diarrhea. *N Engl J Med* 2006; **355**: 270–80.
- 10 Wiedenmann B, John M, Ahnert-Hilger G, Riecken EO. Molecular and cell biological aspects of neuroendocrine tumors of the gastroenteropancreatic system. *J Mol Med* 1998; **76**: 637–47.
- 11 Modlin IM, Kidd M, Pfragner R, et al. The functional characterization of normal and neoplastic human enterochromaffin cells. *J Clin Endocrinol Metab* 2006; **91**: 2340–48.
- 12 Bloom SR. Gut hormones. Edinburgh: Churchill Livingstone, 1978.
- 13 Kidd M, Modlin IM, Tang LH. Gastrin and the enterochromaffin-like cell: an acid update. *Dig Surg* 1998; **15**: 209–17.
- 14 Hanahan D. Heritable formation of pancreatic beta-cell tumours in transgenic mice expressing recombinant insulin/simian virus 40 oncogenes. *Nature* 1985; **315**: 115–22.
- 15 Rane SG, Dubus P, Mettus RV, et al. Loss of Cdk4 expression causes insulin-deficient diabetes and Cdk4 activation results in beta-islet cell hyperplasia. *Nat Genet* 1999; **22**: 44–52.
- 16 Franklin DS, Godfrey VL, O'Brien DA, et al. Functional collaboration between different cyclin-dependent kinase inhibitors suppresses tumor growth with distinct tissue specificity. *Mol Cell Biol* 2000; **20**: 6147–58.
- 17 Yang HW, Kutok JL, Lee NH, et al. Targeted expression of human MYCN selectively causes pancreatic neuroendocrine tumors in transgenic zebrafish. *Cancer Res* 2004; **64**: 7256–62.
- 18 Nilsson O, Wangberg B, Johansson L, et al. *Praomys (Mastomys) natalensis*: a model for gastric carcinoid formation. *Yale J Biol Med* 1992; **65**: 741–51.
- 19 Fossmark R, Martinsen TC, Bakkelund KE, et al. ECL-cell derived gastric cancer in male cotton rats dosed with the H2-blocker loxidine. *Cancer Res* 2004; **64**: 3687–93.
- 20 Bertolino P, Tong WM, Herrera PL, et al. Pancreatic beta-cell-specific ablation of the multiple endocrine neoplasia type 1 (MEN1) gene causes full penetrance of insulinoma development in mice. *Cancer Res* 2003; **63**: 4836–41.
- 21 Crabtree JS, Scacheri PC, Ward JM, et al. A mouse model of multiple endocrine neoplasia, type 1, develops multiple endocrine tumors. *Proc Natl Acad Sci USA* 2001; **98**: 1118–23.
- 22 Biondi CA, Gartside MG, Waring P, et al. Conditional inactivation of the *MEN1* gene leads to pancreatic and pituitary tumorigenesis but does not affect normal development of these tissues. *Mol Cell Biol* 2004; **24**: 3125–31.
- 23 Parekh D, Ishizuka J, Townsend CM Jr, et al. Characterization of a human pancreatic carcinoid in vitro: morphology, amine and peptide storage, and secretion. *Pancreas* 1994; **9**: 83–90.
- 24 Kolby L, Bernhardt P, Ahlman H, et al. A transplantable human carcinoid as model for somatostatin receptor-mediated and amine transporter-mediated radionuclide uptake. *Am J Pathol* 2001; **158**: 745–55.
- 25 Leotlela PD, Jauch A, Holtgreve-Grez H, Thakker RV. Genetics of neuroendocrine and carcinoid tumours. *Endocr Relat Cancer* 2003; **10**: 437–50.
- 26 Modlin IM, Kidd M, Latich I, et al. Current status of gastrointestinal carcinoids. *Gastroenterology* 2005; **128**: 1717–51.
- 27 Tonnie H, Toliat MR, Ramel C, et al. Analysis of sporadic neuroendocrine tumours of the enteropancreatic system by comparative genomic hybridisation. *Gut* 2001; **48**: 536–41.
- 28 Thakker RV. Multiple endocrine neoplasia type 1. In: DeGroot LJ, Jameson JL, eds. *Endocrinology*, 5th edn. Philadelphia, USA: Elsevier Saunders, 2006: 3509–21.
- 29 Lollgen RM, Hessman O, Szabo E, et al. Chromosome 18 deletions are common events in classical midgut carcinoid tumors. *Int J Cancer* 2001; **92**: 812–15.
- 30 DeLellis RA, Lloyd RV, Heitz PU, Eng C, eds. World Health Organization classification of tumours, pathology and genetics of tumours of endocrine organs. Lyon: IARC Press, 2004.
- 31 Anlauf M, Perren A, Meyer CL, et al. Precursor lesions in patients with multiple endocrine neoplasia type 1-associated duodenal gastrinomas. *Gastroenterology* 2005; **128**: 1187–98.
- 32 Kaltsas GA, Besser GM, Grossman AB. The diagnosis and medical management of advanced neuroendocrine tumors. *Endocr Rev* 2004; **25**: 458–511.
- 33 Eriksson B, Oberg K, Stridsberg M. Tumor markers in neuroendocrine tumors. *Digestion* 2000; **62** (suppl 1): 33–38.
- 34 Moller JE, Pellikka PA, Bernheim AM, et al. Prognosis of carcinoid heart disease: analysis of 200 cases over two decades. *Circulation* 2005; **112**: 3320–27.
- 35 Berna MJ, Hoffmann KM, Long SH, et al. Serum gastrin in Zollinger-Ellison syndrome: II. Prospective study of gastrin provocative testing in 293 patients from the National Institutes of Health and comparison with 537 cases from the literature. Evaluation of diagnostic criteria, proposal of new criteria, and correlations with clinical and tumoral features. *Medicine (Baltimore)* 2006; **85**: 331–64.
- 36 Stridsberg M, Oberg K, Li Q, et al. Measurement of chromogranin A, chromogranin B (secretogranin I), chromogranin C (secretogranin II) and pancreastatin in plasma and urine from patients with carcinoid tumours and endocrine pancreatic tumours. *J Endocrinol* 1995; **144**: 49–59.
- 37 Kloppel G, Perren A, Heitz PU. The gastroenteropancreatic neuroendocrine cell system and its tumors: the WHO classification. *Ann N Y Acad Sci* 2004; **1014**: 13–27.
- 38 Lloyd RV. Practical markers used in the diagnosis of neuroendocrine tumors. *Endocr Pathol* 2003; **14**: 293–301.
- 39 Saqi A, Alexis D, Remotti F, Bhagat G. Usefulness of CDX2 and TTF-1 in differentiating gastrointestinal from pulmonary carcinoids. *Am J Clin Pathol* 2005; **123**: 394–404.
- 40 Gastrointestinal carcinoid tumours. In: Modlin IM, Gustafsson BI, Kidd M, eds. *Advances in digestive disease*. Bethesda, MD: AGA Institute Press, 2007: 203–18.
- 41 Anderson MA, Carpenter S, Thompson NW, et al. Endoscopic ultrasound is highly accurate and directs management in patients with neuroendocrine tumors of the pancreas. *Am J Gastroenterol* 2000; **95**: 2271–77.
- 42 Gibril F, Jensen RT. Diagnostic uses of radiolabelled somatostatin receptor analogues in gastroenteropancreatic endocrine tumours. *Dig Liver Dis* 2004; **36** (suppl 1): S106–20.
- 43 Gibril F, Reynolds JC, Doppman JL, et al. Somatostatin receptor scintigraphy: its sensitivity compared with that of other imaging methods in detecting primary and metastatic gastrinomas. A prospective study. *Ann Intern Med* 1996; **125**: 26–34.
- 44 Adams S, Baum R, Rink T, et al. Limited value of fluorine-18 fluorodeoxyglucose positron emission tomography for the imaging of neuroendocrine tumours. *Eur J Nucl Med* 1998; **25**: 79–83.
- 45 Koopmans KP, de Vries EG, Kema IP, et al. Staging of carcinoid tumours with 18F-DOPA PET: a prospective, diagnostic accuracy study. *Lancet Oncol* 2006; **7**: 728–34.
- 46 Montravers F, Grahek D, Kerrou K, et al. Can fluorodihydroxyphenylalanine PET replace somatostatin receptor scintigraphy in patients with digestive endocrine tumors? *J Nucl Med* 2006; **47**: 1455–62.
- 47 Orlefors H, Sundin A, Garske U, et al. Whole-body (11)C-5-hydroxytryptophan positron emission tomography as a universal imaging technique for neuroendocrine tumors: comparison with somatostatin receptor scintigraphy and computed tomography. *J Clin Endocrinol Metab* 2005; **90**: 3392–400.
- 48 Koukouraki S, Strauss LG, Georgoulas V, et al. Evaluation of the pharmacokinetics of 68Ga-DOTATOC in patients with metastatic neuroendocrine tumours scheduled for 90Y-DOTATOC therapy. *Eur J Nucl Med Mol Imaging* 2006; **33**: 460–66.
- 49 D'Onofrio M, Zamboni G, Faccioli N, et al. Ultrasonography of the pancreas. 4. Contrast-enhanced imaging. *Abdom Imaging* 2007; **32**: 171–81.
- 50 Hyslop WB, Balci NC, Semelka RC. Future horizons in MR imaging. *Magn Reson Imaging Clin N Am* 2005; **13**: 211–24.

- 51 Funovics MA, Kapeller B, Hoeller C, et al. MR imaging of the her2/neu and 9.2.27 tumor antigens using immunospecific contrast agents. *Magn Reson Imaging* 2004; **22**: 843–50.
- 52 Thorek DL, Chen AK, Czupryna J, Tsourkas A. Superparamagnetic iron oxide nanoparticle probes for molecular imaging. *Ann Biomed Eng* 2006; **34**: 23–38.
- 53 van Tuyl SA, van Noorden JT, Timmer R, et al. Detection of small-bowel neuroendocrine tumors by video capsule endoscopy. *Gastrointest Endosc* 2006; **64**: 66–72.
- 54 Yamaguchi T, Manabe N, Tanaka S, et al. Multiple carcinoid tumors of the ileum preoperatively diagnosed by enteroscopy with the double-balloon technique. *Gastrointest Endosc* 2005; **62**: 315–18.
- 55 Plockinger U, Rindi G, Arnold R, et al. Guidelines for the diagnosis and treatment of neuroendocrine gastrointestinal tumours. A consensus statement on behalf of the European Neuroendocrine Tumour Society (ENETS). *Neuroendocrinology* 2004; **80**: 394–424.
- 56 Norton JA. Surgery for primary pancreatic neuroendocrine tumors. *J Gastrointest Surg* 2006; **10**: 327–31.
- 57 Norton JA. Endocrine tumours of the gastrointestinal tract. Surgical treatment of neuroendocrine metastases. *Best Pract Res Clin Gastroenterol* 2005; **19**: 577–83.
- 58 Ahlman H. Surgical treatment of carcinoid tumours of the stomach and small intestine. *Ital J Gastroenterol Hepatol* 1999; **31** (suppl 2): S198–201.
- 59 Sarmiento JM, Farnell MB, Que FG, Nagorney DM. Pancreaticoduodenectomy for islet cell tumors of the head of the pancreas: long-term survival analysis. *World J Surg* 2002; **26**: 1267–71.
- 60 Norton JA, Alexander HR, Fraker DL, et al. Does the use of routine duodenotomy (DUODX) affect rate of cure, development of liver metastases, or survival in patients with Zollinger-Ellison syndrome? *Ann Surg* 2004; **239**: 617–25.
- 61 Norton JA, Jensen RT. Resolved and unresolved controversies in the surgical management of patients with Zollinger-Ellison syndrome. *Ann Surg* 2004; **240**: 757–73.
- 62 van Vilsteren FG, Baskin-Bey ES, Nagorney DM, et al. Liver transplantation for gastroenteropancreatic neuroendocrine cancers: defining selection criteria to improve survival. *Liver Transpl* 2006; **12**: 448–56.
- 63 Benjergard SA, Forssell-Aronsson E, Wangberg B, et al. Intraoperative tumour detection using <sup>111</sup>In-DTPA-D-Phe1-octreotide and a scintillation detector. *Eur J Nucl Med* 2001; **28**: 1456–62.
- 64 O'Toole D, Ruzzniewski P. Chemoembolization and other ablative therapies for liver metastases of gastrointestinal endocrine tumours. *Best Pract Res Clin Gastroenterol* 2005; **19**: 585–94.
- 65 Roche A, Girish BV, de Baere T, et al. Prognostic factors for chemoembolization in liver metastasis from endocrine tumors. *Hepatogastroenterology* 2004; **51**: 1751–56.
- 66 Chung JW, Park JH, Han JK, et al. Hepatic tumors: predisposing factors for complications of transcatheter oily chemoembolization. *Radiology* 1996; **198**: 33–40.
- 67 Mazzaglia PJ, Berber E, Milas M, Siperstein AE. Laparoscopic radiofrequency ablation of neuroendocrine liver metastases: a 10-year experience evaluating predictors of survival. *Surgery* 2007; **142**: 10–19.
- 68 Shojamanesh H, Gibril F, Louie A, et al. Prospective study of the antitumor efficacy of long-term octreotide treatment in patients with progressive metastatic gastrinoma. *Cancer* 2002; **94**: 331–43.
- 69 Panzuto F, Di Fonzo M, Iannicelli E, et al. Long-term clinical outcome of somatostatin analogues for treatment of progressive, metastatic, well-differentiated entero-pancreatic endocrine carcinoma. *Ann Oncol* 2006; **17**: 461–66.
- 70 Kolby L, Persson G, Franzen S, Ahren B. Randomized clinical trial of the effect of interferon alpha on survival in patients with disseminated midgut carcinoid tumours. *Br J Surg* 2003; **90**: 687–93.
- 71 Kouvaraki MA, Ajani JA, Hoff P, et al. Fluorouracil, doxorubicin, and streptozocin in the treatment of patients with locally advanced and metastatic pancreatic endocrine carcinomas. *J Clin Oncol* 2004; **22**: 4762–71.
- 72 Yao JC, Ng C, Hoff PM, et al. Improved progression free survival (PFS), and rapid, sustained decrease in tumor perfusion among patients with advanced carcinoid treated with bevacizumab. *Proc Am Soc Clin Oncol* 2005; **23**: 309 (abstr).
- 73 Kulke M, Henz J, Meropolo NJ, et al. A phase 2 study to evaluate the efficacy and safety of SU11248 in patients (pts) with unresectable neuroendocrine tumors (NETs). *Proc Am Soc Clin Oncol* 2005; **23**: 310 (abstr).
- 74 Duran I, Kortmansky J, Singh D, et al. A phase II clinical and pharmacodynamic study of temsirolimus in advanced neuroendocrine carcinomas. *Br J Cancer* 2006; **95**: 1148–54.
- 75 Yao JC, Phan AT, Jacobs C, et al. Phase II study of RAD001 (everolimus) and depot octreotide (sandostatin LAR) in patients with advanced low grade neuroendocrine carcinoma (LGNET). *Proc Am Soc Clin Oncol Gastro Cancers Symp* 2006; abstr 178.
- 76 Therasse P, Arbuck SG, Eisenhauer EA, et al. New guidelines to evaluate the response to treatment in solid tumors. European Organization for Research and Treatment of Cancer, National Cancer Institute of the United States, National Cancer Institute of Canada. *J Natl Cancer Inst* 2000; **92**: 205–16.
- 77 Forrer F, Valkema R, Kwekkeboom DJ, et al. Peptide receptor radionuclide therapy. *Best Pract Res Clin Endocrinol Metab* 2007; **21**: 111–29.
- 78 Lepage C, Racht B, Coleman MP. Survival from malignant digestive endocrine tumors in England and Wales: a population-based study. *Gastroenterology* 2007; **132**: 899–904.